

Original article

Tumour and target volumes in permanent prostate brachytherapy: A supplement to the ESTRO/EAU/EORTC recommendations on prostate brachytherapy

Carl Salembier^a, Pablo Lavagnini^b, Philippe Nickers^c, Paola Mangili^d, Alex Rijnders^a, Alfredo Polo^e, Jack Venselaar^f, Peter Hoskin^{g,*}, on behalf of the PROBATE group of GEC ESTRO

^aDepartment of Radiation Oncology, Europe Hospitals, Brussels, Belgium, ^bDepartment of Radiation Oncology, MultiMedica Institute, Milan, Italy, ^cDepartment of Radiation Oncology, Domaine Universitaire du Sart Tilman, Liège, Belgium, ^dDepartment of Medical Physics, IRCCS, S-Raffaele, Milan, Italy, ^eDepartment of Radiation Oncology, Catalan Institute of Oncology, Barcelona, Spain, ^fDepartment of Radiotherapy, Dr B. Verbeeten Institute, Tilburg, The Netherlands, ^gMount Vernon Cancer Centre, Northwood, UK

Abstract

The aim of this paper is to supplement the GEC/ESTRO/EAU recommendations for permanent seed implantations in prostate cancer to develop consistency in target and volume definition for permanent seed prostate brachytherapy.

Recommendations on target and organ at risk (OAR) definitions and dosimetry parameters to be reported on post implant planning are given.

© 2007 Published by Elsevier Ireland Ltd. Radiotherapy and Oncology xx (2007) xxx–xxx.

Keywords: Prostate cancer; LDR-brachytherapy; Seed brachytherapy; Dosimetry

Prostate cancer is an increasing health problem in Europe. The present treatment options include radical prostatectomy, external beam radiation therapy, temporary and permanent brachytherapy, hormonal therapy and watchful waiting.

In the treatment of early prostate cancer, transperineal ultra-sound guided brachytherapy using permanent implants of iodine-125 or palladium-103 has proven itself as an alternative therapy to radical prostatectomy with equivalent medium and long-term results [16,32,63,65,66,70]. Since the mid-1990s, a rapid expansion of the number of permanent implants for early stage prostate cancer occurred in the USA. An identical situation is now observed in Europe [11,79,80].

Guidelines and recommendations on permanent seed implantation are available in the literature to provide a guide for those embarking on brachytherapy [4,48,49]. These tend to focus on the indications for and techniques of implantation with limited attention to post implant evaluation and dosimetry. There is now a large literature on pre- and post-implant dosimetry using different techniques and modalities, but none is considered standard [1,8,12,13,23,27,28,30,32,40,42,47,50,59,75]. In particular there is no consistent definition of clinical target volume (CTV), planning target volume (PTV) or defined boundaries for the organs at risk (OARs).

In some articles, the pre-implant transrectal ultrasound (TRUS) definition of the prostate is named GTV (gross tumour volume) [26,54], in others GTV (gross target volume – an acronym of ICRU terms) [33], in others CTV (clinical target volume) and in others TV (target volume) or PTV (planning target volume) [44,46,69]. On the other hand, as soon as a margin is added around the “prostate contour”, the PTV (planning target volume) definition is applied, regardless of the reason or origin of this margin. For post-plan target volumes, either “prostate” or “PTV” and even a unique term “evaluated target volume” (ETV) are seen in the literature.

The ESTRO/EAU/EORTC recommendations on permanent seed implantation for localized prostate cancer were published in 2000 [4]. In this publication, little information is given on target (prostate gland) or organs at risk (prostatic urethra, rectum) contouring, target definition, dosimetric parameters regarding target dosimetry or dosimetric parameters regarding organs at risk. With the dramatic rise in the number of implants performed in the last five years, both in the USA and in Europe, there is an ever-increasing literature on dosimetric parameters and of clinical outcome but no common definition of the CTV, PTV or OARs. Based on an extensive review of the literature and informed by the GEC ESTRO European questionnaire results [38,41] these recommendations have

been produced by the Prostate Working Party of the GEC ESTRO. They have been written to harmonise and cross reference to the other guidelines produced on HDR prostate brachytherapy and those from the Gynaecology group of GEC ESTRO [29,36,60].

ICRU definitions related to LDR prostate brachytherapy

ICRU definitions [35]

Gross tumour volume (GTV). The gross tumour volume corresponds to the gross palpable, visible or clinically demonstrable location and extent of the malignant growth.

Given the TNM definition for prostate cancer, GTV can only be defined for tumour stages larger than T1c. For these tumour stages (>T1c), the GTV definition can be useful, certainly in cases where the tumour area can be identified, not only by digital rectal examination, but also by radiological examinations including transrectal ultrasound, magnetic resonance imaging and spectroscopy. In T3 disease extension through the capsule or into the seminal vesicles may be seen on imaging and included in the GTV although in general such patients will not be included in a seed brachytherapy programme.

Clinical target volume (CTV). The clinical target volume is the volume that contains the GTV and includes subclinical malignant disease at a certain probability level. Delineation of the CTV is based on the probability of subclinical malignant cells present outside the GTV.

Prostate cancer has recognised paths of microscopic spread through the capsule and into the seminal vesicles, which may occur even in very early stage prostate cancer. **Probability of microscopic extension at different distances around the GTV.** It is well documented in surgical literature that prostate cancer is in the majority of cases a 'whole gland' disease. Even in a very early stage, prostate cancer presents as a multi-focal disease – both lobes can contain microscopic disease. Given this specific behaviour, at least

the whole prostate gland has to be considered as 'target' and included in the CTV.

Probability of subclinical invasion of the peri-prostatic tissues. When available, a magnetic resonance scan of the prostate, ideally using an endorectal coil, should be performed for radiological staging and in particular to identify those patients with T3 disease (Fig. 3) [7].

For very early stage tumours (T1c – T2) the probability of capsular penetration is related to the tumour stage (T1c < T2), iPSA and Gleason score as demonstrated in the Partin tables (Table 1) [55–57]. These tables show that even tumours with stage T1c and T2, independent of Gleason score or iPSA, have a probability of established capsular penetration of at least ten percent.

Extent of subclinical extraprostatic extension of early prostate cancer. Studies on specimens obtained by radical prostatectomy show a tendency for clinical understaging of capsular penetration, with rates ranging from 40% to 60% [10,24,52,58,73]. Only a few authors have focussed on the geometrical extent of extraprostatic disease. The largest study included 376 specimens from patients undergoing radical retropubic prostatectomy using whole organ mount examination of the extraprostatic extension (EPE) [19]. This identified EPE in 28% of examined cases. The radial EPE distance in these specimens had a mean of 0.8 mm (range 0.04–4.4 mm) and a median of 0.5 mm. Ninety-six percent of all specimens with EPE had a radial EPE distance ≤ 2.5 mm. All patients classified in the good prognostic risk group (PSA < 10, Gleason < 7) had a radial EPE distance < 3 mm (Table 2).

Planning target volume (PTV). The PTV surrounds the CTV with a margin to compensate for the uncertainties in treatment delivery.

The PTV is a geometric concept, introduced for treatment planning. A margin must be added to the CTV either to compensate for expected physiological movements and variations in size, shape and position of the CTV during therapy (internal margin) or for uncertainties (inaccuracies and lack of reproducibility) in patient set-up during irradiation, which may be random or systematic.

Table 1
Probability of organ confined disease in very early prostate cancer (based on the Partin tables) [55]

Gleason score	T1c	T2a	T2b	T2c
PSA 2.6–4.0				
2–4	92% (82–98)	85% (69–96)	80% (61–95)	78% (58–94)
5–6	84% (81–86)	71% (66–75)	63% (57–59)	61% (50–70)
PSA 4.1–6.0				
2–4	90% (78–98)	81% (63–95)	75% (55–93)	73% (52–93)
5–6	80% (78–83)	66% (62–70)	57% (52–63)	55% (44–64)
PSA 6.1–10.0				
2–4	87% (73–97)	76% (56–94)	69% (47–91)	67% (45–91)
5–6	75% (72–77)	58% (54–61)	49% (43–54)	46% (36–56)

Figure in brackets are 95% confidence intervals.

Table 2
Dosimetry parameters for organs at risk

Preplan	Postplan
Rectum	
D_{2cc}	D_{2cc}
$D_{0.1cc}(\sim D_{max})$	V_{100}
	V_{150}
Urethra	
D_{10}	D_{10}
D_{30}	D_{30}
	D_5

The CTV to PTV margin can be minimised in brachytherapy because there are no significant opportunities for set up error.

It is now possible to perform LDR-prostate-brachytherapy as a one-stop procedure within 60–90 min. Variation in the position of the prostate gland during implantation can be minimised using locking stabilisation needles and by the use of on-line “real-time” verification mechanisms. Later changes in the size or shape of the prostate immediately after implantation are only temporarily related to procedure-induced oedema. This oedema normally resolves within the first half-life of the radioactive seeds as shown in post-implant radiological examinations [13,22,64,81,83,86].

In prostate brachytherapy there are uncertainties in seed placement, and even here, the uncertainties can be minimised. In the original two-stage preplanned approach, seed placement uncertainty was 3 and 5 mm in the longitudinal and in the transverse directions, respectively [6,68]. Correct delivery of the seeds in an exact x/y direction can nowadays be guaranteed given the superposition of the implantation grid on the ultrasound images all through the prostate. Correct delivery of the seeds in the longitudinal (z) direction can be more difficult. Once again, available software and the correct use of continuous on-line verification of ultrasound position coupled with fluoroscopy can substantially reduce this uncertainty [12,61,76,78,87].

Practical considerations

The actual clinical practice in most European centres can be summarised by: (1) no use of the GTV definition (2) CTV equals the prostate gland and (3) PTV corresponds to the CTV plus a margin [38].

Prescription and reporting – definitions and parameters

ICRU definitions for dose prescription

Gross tumour volume. Whenever possible the GTV should be contoured on the pre-implantation ultrasound-acquired images. Where necessary, correlation with endorectal coil magnetic resonance and spectroscopy should be used.

Clinical target volume. The clinical target volume for pre-implant dosimetry should be the prostate gland with a margin as shown in Fig. 1 (Fig. 1).

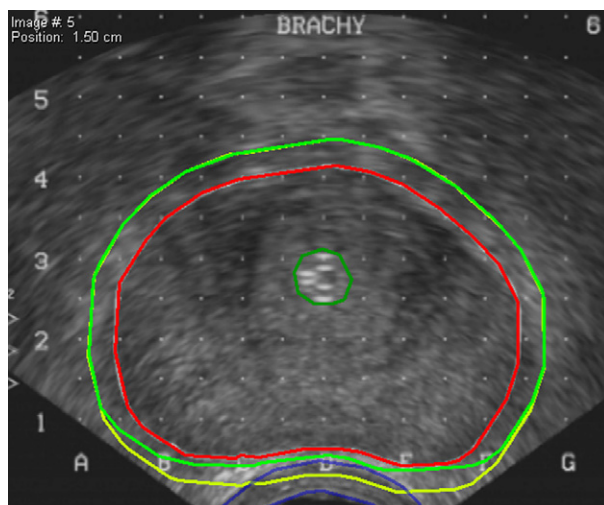


Fig. 1. Preplanning CTV definitions. —, prostate contour; —, urethra prostatica; —, clinical target volume (three-dimensional expansion of the prostate – 3 mm in each direction); —, clinical target volume constrained to the anterior rectal wall (three-dimensional expansion of the prostate – 3 mm in each direction BUT 0 mm in the posterior direction).

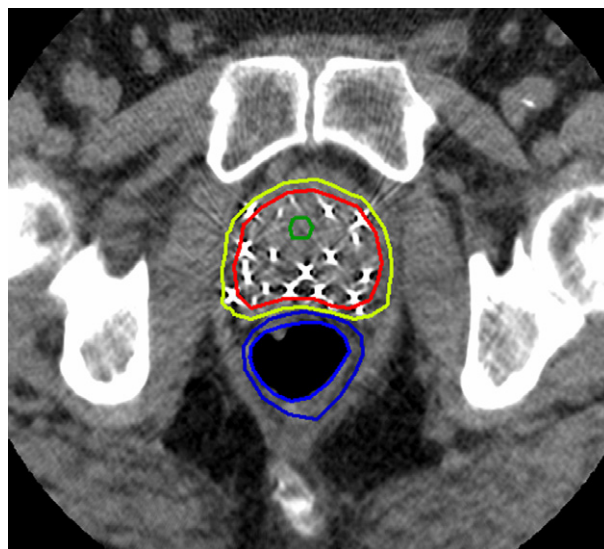


Fig. 2. Post-plan definitions of CTV. Legend: —, CTV-P = CTV-prostate; —, CTV-PM = CTV-prostate margin; —, urethra prostatica; —, rectum (outer and inner wall).

For T1 – T2 prostate cancer the CTV corresponds to the visible contour of the prostate expanded with a three-dimensional volume expansion of 3 mm.

This three-dimensional expansion can be constrained to the anterior rectal wall (posterior direction) and the bladder neck (cranial direction).

For T3 tumours, the CTV corresponds to the visible contour of the prostate including visible extension due to extracapsular growth which is then expanded with

a three-dimensional expansion of three millimetres in each direction, with rectal and bladder constraints as above.

Planning target volume. Using online in vivo 3-D dosimetry and fluoroscopy in addition to sonography to eliminate errors due to seed placement, there is no need for an expansion from the CTV to define the PTV, i.e., PTV = CTV.

Organs at risk. Different organs at risk can be defined in the pre-implantation setting [4,15,82,87].

- (a) Prostatic urethra: common practice to obtain visualisation of the urethra is to use a urinary catheter. This should be a small gauge catheter, French gauge 10, to avoid distension of the urethra. The surface of the catheter is used to define the urethral surface from the prostatic base to apex. However in practice the urethra is not a circular structure and an alternative which may give a more accurate anatomical picture is to instil aerated gel into the urethra prior to obtaining the ultrasound images.
- (b) Rectum: using transrectal ultrasound, visualisation of the anterior rectal wall is no problem but may introduce artefacts due to displacement and distension. Many simply outline the outer wall and this should be regarded as the minimum requirement; others define outer and inner walls to define a doughnut as shown in Fig. 1. In terms of the critical cells in the rectum for late damage the latter is probably more correct. For defining small volumes up to 5cc outlining the outer wall alone is therefore sufficient. This is in keeping with the recommendations in the Gynaecology recommendations.
- (c) Penile bulb and/or neurovascular bundles: currently this remains investigational.

Recommended prescription doses

The AAPM-TG-64 recommendations are universally implemented [80,85]. The standard dose to the 100% isodose is 145 Gy for low dose rate ^{125}I seeds and 125 Gy for 103Pd. (NIST 99) [51,67,84].

Dosimetric parameters related to ICRU definitions for dose prescription

Gross tumour volume. The GTV should be encompassed by the 150% isodose.

Clinical target volume (equals planning target volume).

Physical parameters correlating with a good pre-implantation dosimetry:

- The V_{100} (the percentage of the CTV that receives the prescribed dose) must be at least 95% ($V_{100} \geq 95\%$ of CTV).
- Therefore, the D_{90} (the dose that covers 90% volume of the CTV) will be larger than the prescription dose ($D_{90} > 100\%$ of prescription dose).

- The V_{150} (the percentage of the CTV that receives 150% of the prescription dose), should be equal to or less than 50% ($V_{150} \leq 50\%$ of CTV).

Organs at risk.

- (a) Rectum:
 - Primary parameter: $D_{2cc} \leq$ reference prescription dose of 145 Gy.
 - Secondary parameter: $D_{0.1cc} (\sim D_{max}) < 200$ Gy.
 it is recommended in common with the other published guidelines that the dose to a very small limited volume (0.1 cm^2) is more appropriate for dose calculation clinical relevance than a maximal dose value [60].
- (b) Prostatic urethra:
 - Primary parameter: $D_{10} < 150\%$ of the prescription dose.
 - Secondary parameter: $D_{30} < 130\%$ of the prescription dose.
- (c) Penile bulb and neurovascular bundles:
 - Investigational at present, no parameters can be reliably defined.

Physical parameters for dose reporting

All implants should undergo post implant evaluation. This should be based on imaging at 4–6 weeks after implantation at which time initial oedema will have settled. Optimal imaging will include MRI but if not available CT alone is adequate.

This ensures good quality control of the implant process and there is now good evidence that the probability of achieving biochemical control is related to the quality of the implant. This can only be evaluated by detailed post-implant dosimetry [74,75,86].

Post-planning – definitions and parameters

Theoretical considerations

The ESTRO-EAU-EORTC guidelines for post-implant evaluation recommend CT-imaging [4]. Image registration with MRI may improve the definition of the CTV for evaluation and decrease the inter-observer variability but CT remains the best means of seed identification [2,13,14,20,23,27,28,30–32,39,40,42,43,47,59,62,74,77].

Seed evaluation. A critical step in post-implant dosimetry is the identification of the seeds in the target region. There is a small risk of seed loss or seed migration. Depending on the implantation technique and on the type of seeds used (loose seeds versus stranded seeds), the migration rates vary between 1% and 15% [9,17,18,25,26,34,37,45,53,72]. For post-implant purposes, the exact number and position of seeds in the target area must be known.

Because the sources appear on more than one CT-slice, a seed location method (seed sorting) based on nearest neighbours needs to be employed. Software algorithms have been developed to find seeds, but the exact number of seeds in the prostate at the time of evaluation is required. All patients should therefore undergo imaging with either plain X-rays of the implanted zone to allow accurate counting with two films at different angles to iden-

tify superimposed seeds. This could also be obtained using CT scout views (topogram). If there are missing seeds, particularly where loose seeds are used a chest X-ray is also recommended.

Once the actual number of seeds in the target area is known, introduction of the number of seeds into the treatment planning system allows localisation of the seeds by the automatic seed finder option. Seed position detection can be performed on either CT or MRI slices. Using CT, scatter around the seeds can complicate this evaluation, but the use of specific filters during the CT-examination may decrease this scatter. On MRI, the seeds are seen as black holes in the organ and individualisation of the different seeds may be more difficult. Some centres prefer the use of ultrasound based post-implant evaluation to define seed positions. The lack of clear visualisation and individualisation of the implanted seeds remains a major problem; developments in seed technology, with more echogenic 'smart' seeds, may aid this process.

Recently two dedicated phantoms for CT and MRI were developed to perform quality assurance of the seed reconstruction procedure [21,71].

Prostate and organ at risk contouring. The accurate contouring of the prostate and organs at risk is essential for useful post implant dosimetry. Several studies have noted discrepancies in volume of the prostate as determined by TRUS, CT and MRI, reflecting the difficulties in differentiating the prostate from the periprostatic musculature and venous plexus using CT. Greatest variations are seen in defining the base and apex of the gland. Whilst CT is the most valuable option for seed positioning, MRI is the most valuable option for organ contouring [2,3,5,13,20,22,43,47,59]. An additional problem is the degree of inter-observer variability in the definition of the prostate volume on post-implant CT and MRI images [1,14,31,40,42]. Close interaction with diagnostic radiologists and training are essential to maximise the potential of the available imaging modalities.

Target definition in relation to the post-plan dosimetry

General considerations. As in the pre-plan situation, a multitude of different definitions are in use. Classical ICRU terms as CTV and PTV, but also terms as ETV (evaluated target volume), are frequently seen in reports on post-implant dosimetry. The exact definition is seldom given and is left to the interpretation of the reader.

Target definitions. Post-implant it is almost always impossible to define a GTV on the radiological images due to interference from the seeds.

CTV and PTV definitions remain the same as stated in Clinical target volume/Planning target volume.

Two different CTV definitions are proposed as shown in Fig. 2.

- (a) CTV-P(rostate) = the post-implant contour of the prostatic gland defined by the capsule on radiological examination.

- (b) CTV-P(rostate)M(argin) = the post-implant contour of the prostatic gland defined by the capsule with a three-dimensional expansion of 3 mm.

Organs at risk. The only OAR that can be reliably defined both on CT and MRI is the rectum. For contouring purposes, using CT only the outer rectal wall can be reliably defined; using MR the outer and inner walls of the rectum over the whole region of interest may be indicated. The lower rectum is poorly defined on CT and best shown with MRI. Image fusion techniques may therefore be of value. However, there is no consistent definition of the rectal volume to be outlined.

The definition of the prostatic urethra is poor on CT and MRI and can only be accurately achieved when a urinary catheter or aerated gel is introduced during post-implant scanning. The recent European questionnaire study [38,41] shows that this is seldom performed. Correlation with or formal fusion of TRUS images with the obtained CT- or MR images may be the optimal non-invasive technique for localisation of the urethra on the post implant scan. Institutional policy should be described if urinary parameters are published.

Defining the penile bulb and neurovascular bundles is only possible with accuracy on MRI.

Dose parameters in the post-implant setting

Target volumes. The primary parameters – D_{90} , V_{100} and V_{150} – should always be reported for both CTV-P and CTV-PM.

Secondary parameters – V_{200} , D_{100} , natural dose rate (NDR), homogeneity index (HI) and conformal index (CI) may also be reported although their value in relation to outcome is not proven and should be a focus for further research.

Organs at risk. D_{2cc} for the rectum and D_{10} for the urethra are at present the primary parameters.

Secondary parameters, $D_{0.1cc}$ and V_{100} for rectum and $D_{0.1cc}$, D_{30} and D_5 for urethra, may also be reported. Volume (V) parameters should be expressed in absolute values (cc).

No parameters can be given at present regarding penile bulb and neurovascular bundles. Further investigation and evaluation is needed.

Conclusions

These recommendations should be considered in conjunction with the ESTRO/EAU/EORTC recommendations on permanent seed implantation for localised prostate cancer which were published in 2000. This guidance was, as noted in the paper, intended for those embarking on brachytherapy to identify the factors related to successful outcome but did not focus on target (prostate gland) or organ at risk (prostatic urethra, rectum) contouring, target definition, dosimetric parameters regarding target dosimetry or dosimetric parameters regarding organs at risk, which is the object of this second publication.

* Corresponding author. P.J. Hoskin, Mount Vernon Cancer Centre, Rickmansworth Road, Northwood, Middlesex, HA6 2RN, UK. E-mail address: peterhoskin@nhs.net

Received 6 November 2006; received in revised form 17 January 2007; accepted 29 January 2007

References

- [1] Al-Qaisieh B. Pre-and post-implant dosimetry: an inter-comparison between UK prostate brachytherapy centres. *Radiother Oncol* 2002;66:181–3.
- [2] Al-Qaisieh B, Ash D, Bottomley DM, et al. Impact of prostate volume evaluation by different observers on CT-based post-implant dosimetry. *Radiother Oncol* 2002;62:267–73.
- [3] Amdur RJ, Gladstone D, Leopold KA, et al. Prostate seed implant quality assessment using MR and CT image fusion. *Int J Radiat Oncol Biol Phys* 1999;43:67–72.
- [4] Ash D, Flynn A, Battermann J, et al. ESTRO/EAU/EORTC recommendations on permanent seed implantation for localized prostate cancer. *Radiother Oncol* 2000;57:315–21.
- [5] Atalar E, Menard C. MR-guided interventions for prostate cancer. *Magn Reson Imaging Clin N Am* 2005;13.
- [6] Blake CC, Elliot TL, Slomba PJ, et al. Variability and accuracy of measurements of prostate brachytherapy seed position in vitro using three-dimensional ultrasound: an intra- and interobserver study. *Med Phys* 2000;27:2788–95.
- [7] Carey BM. Imaging for prostate cancer. *Clin Oncol (R Coll Radiol)* 2005;17:553–9.
- [8] Chauveinc L, Flam T, Solignac S, et al. Prostate cancer brachytherapy: Is real-time ultrasound-based dosimetry predictive of subsequent CT-based dose distribution calculation? A study of 450 patients by the Institut Curie/Hospital Cochin (Paris) Group. *Int J Radiat Oncol Biol Phys* 2004;59:691–5.
- [9] Chauveinc L, Osseil A, Flam T, et al. Iodine 125 seed migration after prostate brachytherapy: a study of 170 patients. *Cancer Radiother* 2004;8:211–6.
- [10] Cookson MS, Fleshner NE, Soloway SM, et al. Correlation between Gleason score of needle biopsy and radical prostatectomy specimen: accuracy and clinical implications. *J Urol* 1997;157:559–62.
- [11] Cooperberg MR, Moul JW, Carroll PR. The changing face of prostate cancer. *J Clin Oncol* 2005;23:8146–51.
- [12] Cormack RA, Tempany CM, D'Amico AV. Optimizing target coverage by dosimetric feedback during prostate brachytherapy. *Int J Radiat Oncol Biol Phys* 2000;48:1245–9.
- [13] Crook J, Mc Lean M, Yeung I, et al. MRI-CT fusion to assess postbrachytherapy prostate volume and the effects of prolonged edema on dosimetry following transperineal interstitial permanent prostate brachytherapy. *Brachytherapy* 2004;3:55–60.
- [14] Crook J, Milosevic M, Catton P, et al. Interobserver variation in postimplant computed tomography contouring affects quality assessment of prostate brachytherapy. *Brachytherapy* 2002;1:66–73.
- [15] Crook JM, Potters L, Stock RG, Zelefsky MJ. Critical organ dosimetry in permanent seed prostate brachytherapy: defining the organs at risk. *Brachytherapy* 2005;4:186–94.
- [16] D'Amico AV, Whittington R, Malkowicz SB, et al. Biochemical outcome after radical prostatectomy, external beam radiation therapy, or interstitial radiation therapy for clinically localized prostate cancer. *JAMA* 1998;280:969–74.
- [17] Davis BJ. Permanent prostate brachytherapy (PPB) as it concerns seed migration and extraprostatic seed placement. *Cancer J* 2005;11:147–51.
- [18] Davis BJ, Haddock MG, Wilson TM, et al. Treatment of extraprostatic cancer in clinically organ-confined prostate cancer by permanent interstitial brachytherapy: is extraprostatic seed placement necessary? *Tech Urol* 2000;6:70–7.
- [19] Davis BJ, Pisansky TM, Wilson TM, et al. The radial distance of extraprostatic extension of prostate carcinoma: implications for prostate brachytherapy. *Cancer* 1999;85:2630–7.
- [20] Debois M, Oyen R, Maes F, et al. The contribution of magnetic resonance imaging to the three-dimensional treatment planning of localized prostate cancer. *Int J Radiat Oncol Biol Phys* 1999;45:857–65.
- [21] De Brabandere M, Kirisits C, Peeters R, et al. Accuracy of seed reconstruction in prostate postplanning studies with a CT- and MRI-compatible phantom. *Radiother Oncol* 2006 [epub ahead of print].
- [22] Dogan Nm Mohideen N, Glasgow GP, et al. Effect of prostatic edema on CT-based post-implant dosimetry. *Int J Radiat Oncol Biol Phys* 2002;53:483–9.
- [23] Dubois DF, Prestidge BR, Hotchkiss LA, et al. Source localization following permanent transperineal prostate interstitial brachytherapy using magnetic resonance imaging. *Int J Radiat Oncol Biol Phys* 1997;39:1037–41.
- [24] Epstein JI. The evaluation of radical prostatectomy specimens performed for carcinoma of the prostate. Therapeutic and prognostic implications. *Pathol Ann* 1991;26:159–210.
- [25] Eshleman JS, Davis BJ, Pisansky TM, et al. Radioactive seed migration to the chest after transperineal interstitial prostate brachytherapy: Extraprostatic seed placement correlates with migration. *Int J Radiat Oncol Biol Phys* 2004;59:419–25.
- [26] Fuller BF, Koziol JA, Feng AC. Prostate brachytherapy seed migration and dosimetry: analysis of stranded sources and other potential predictive factors. *Brachytherapy* 2004;3:10–9.
- [27] CT-ultrasound fusion prostate brachytherapy: a dynamic dosimetry feedback and improvement method – A report of 54 consecutive cases. Fuller DB, Jin H, Kowiol JA, Feng AC. *Brachytherapy* 2005;4:207–16.
- [28] Gong L, Cho PS, Han BH, et al. Ultrasonography and fluoroscopic fusion for prostate brachytherapy dosimetry. *Int J Radiat Oncol Biol Phys* 2002;54:1322–30.
- [29] Haie-Meder C, Pötter R, Van Limbergen E, et al. Recommendations from Gynaecological (GYN) GEC-ESTRO Working Group (I): concepts and terms in 3D image based 3D treatment planning in cervix cancer brachytherapy with emphasis on MRI assessment of GRV and CTV. *Radiother Oncol* 2005;74:235–45.
- [30] Han BH, Wallner K, Merrick G, et al. Prostate brachytherapy seed identification on post-implant TRUS images. *Med Phys* 2003;30:898–900.
- [31] Han BH, Wallner K, Merrick G, et al. The effect of interobserver differences in post-implant prostate CT image interpretation on dosimetric parameters. *Med Phys* 2003;30:1096–102.
- [32] Haustermans K, Hofland I, Van Poppel H, et al. Cell kinetic measurements in prostate cancer. *Int J Radiat Oncol Biol Phys* 1997;37:1067–70.
- [33] Haworth A, Ebert M, St.Clair S, et al. Impact of selection of post-implant technique on dosimetry parameters for permanent prostate implants. *Brachytherapy* 2005;4:146–53.
- [34] Horwitz EM, Mitra RK, Uzzo RG, et al. Impact of target volume coverage with Radiation Therapy Oncology Group (RTOG) 98-05 guidelines for transrectal ultrasound guided permanent Iodine-125 prostate implants. *Radiother Oncol* 2003;66:173–9.
- [35] ICRU Report 58. Dose and volume specification for reporting interstitial brachytherapy, International Commission on Radiation Units and Measurements, ICRU, Bethesda, Maryland, USA; 1997.
- [36] Kovacs G, Potter R, Loch T, et al. GEC/ESTRO-EAU recommendations on temporary brachytherapy using stepping source

- es for localised prostate cancer. *Radiother Oncol* 2005;74:137–48.
- [37] Kunos CA, Resnick MI, Kinsella TJ, et al. Migration of implanted free radioactive seeds for adenocarcinoma of the prostate using a Mick applicator. *Brachytherapy* 2004;3:71–7.
- [38] Lavagnini P, Mangili P, Venselaar J. Recommendations of the Braphyqs Prostate Sub-Group, the clinical part of the questionnaire. *Radiother Oncol* 2005;75:S22, abstract 49.
- [39] Lee WR, deGuzman AF, Bare RL, et al. Postimplant analysis of transperineal interstitial permanent prostate brachytherapy: evidence for a learning curve in the first year at a single institution. *Int J Radiat Oncol Biol Phys* 2000;46:83–8.
- [40] Lee WR, Roach M, Michalski J, et al. Interobserver variability leads to significant differences in quantifiers of prostate implant adequacy. *Int J Radiat Oncol Biol Phys* 2002;54:457–61.
- [41] Mangili P, Lavagnini P, Venselaar J. Recommendations of the Braphyqs Prostate Sub-Group, the physics part of the questionnaire. *Radiother Oncol* 2005;75:S23, abstract 50.
- [42] Mangili P, Stea L, Cattani F, et al. Comparative study of permanent interstitial prostate brachytherapy post-implant evaluation among seven Italian institutes. *Radiother Oncol* 2004;71:13–21.
- [43] McLaughlin PW, Narayana V, Drake DG, et al. Comparison of MRI pulse sequences in defining prostate volume after permanent implantation. *Int J Radiat Oncol Biol Phys* 2002;54:703–11.
- [44] Merrick GS, Butler WM. Modified uniform seed loading for prostate brachytherapy: rationale, design and evaluation. *Tech Urol* 2000;6:78.
- [45] Merrick GS, Butler WM, Dorsey AT, et al. Seed fixicity in the prostate/periprostatic region following brachytherapy. *Int J Radiat Oncol Biol Phys* 2000;46:215–20.
- [46] Merrick GS, Wallner K, Butler W. Permanent interstitial brachytherapy for the management of carcinoma of the prostate gland. *J Urol* 2003;169:1643–52.
- [47] Moerland MA, Wijrdeman HK, Beersma R, et al. Evaluation of permanent I-125 prostate implants using radiography and magnetic resonance imaging. *Int J Radiat Oncol Biol Phys* 1997;37:927–33.
- [48] Nag S, Bice W, DeWyngaert K, et al. The American Brachytherapy Society recommendations for permanent prostate brachytherapy post-implant dosimetric analysis. *Int J Radiat Oncol Biol Phys* 2000;46:221–30.
- [49] Nag S, Beyer D, Friedland J, Nath R. American Brachytherapy Society (ABS) recommendations for transperineal permanent brachytherapy of prostate cancer. *Int J Radiat Oncol Biol Phys* 1999;44:789.
- [50] Narayana V, Roberson PL, Pu AT, et al. Impact of differences in ultrasound and computed tomography volumes on treatment planning of permanent prostate implants. *Int J Radiat Oncol Biol Phys* 1997;37:1181–5.
- [51] Nath R, Anderson LL, Luxton G, et al. Dosimetry of interstitial brachytherapy sources: recommendations of the AAPM Radiation Therapy Committee Task Group No 43. *Med Phys* 1995;22:209–34.
- [52] Oesterling JE, Brendler CB, Epstein JI, et al. Correlation of clinical stage, serum prostatic acid phosphatase and preoperative Gleason grade with final pathologic stage in 275 patients with clinically localized adenocarcinoma of the prostate. *J Urol* 1987;138:92–8.
- [53] Older RA, Snyder B, Krupski TL, et al. Radioactive implant migration in patients treated for localized prostate cancer with interstitial brachytherapy. *J Urol* 2001;165:1590–2.
- [54] Ove R, Wallner K, Badiozamani K, Korjesson T, Sutlief S. Standardization of prostate brachytherapy treatment plans. *Int J Radiat Oncol Biol Phys* 2001;50:257–63.
- [55] Partin AW, Carter HB, Chan DW, et al. Prostate specific antigen in the staging of localised prostate cancer: influence of tumour differentiation, tumour volume and benign hyperplasia. *J Urol* 1990;143:747–52.
- [56] Partin AW, Epstein JI, Cho KR, et al. Morphometric measurements of tumor volume and per cent of gland involvement as predictor of pathological stage in clinical stage B prostate cancer. *J Urol* 1989;141:341–5.
- [57] Partin AW, Kattan MW, Subong EN, et al. Combination of prostate specific antigen, clinical stage and Gleason score to predict pathologic stage of localised prostate cancer. *JAMA* 1997;277:1445–51.
- [58] Peller PA, Young DC, Marmaduke DP, et al. Sextant prostate biopsies. A histopathologic correlation with radical prostatectomy specimen. *Cancer* 1995;75:530–8.
- [59] Polo A, Cattani F, Vavassori A, et al. MR and CT image fusion for postimplant analysis in permanent prostate seed implants. *Int J Radiat Oncol Biol Phys* 2004;60:1572–9.
- [60] Pötter R, Haie-Meder C, Van Limbergen E, et al. Recommendations from gynaecological (GYN) GEC ESTRO working group (II): concepts and terms in 3D image based treatment planning in cervix cancer brachytherapy – 3D dose volume parameters and aspects of 3D image-based anatomy, radiations physics, radiobiology. *Radiother Oncol* 2006;78:67–77.
- [61] Potters L, Calugaru E, Thornton KB, et al. Towards a dynamic real-time intraoperative permanent prostate brachytherapy methodology. *Brachytherapy* 2003;2:172–80.
- [62] Potters L, Cao Y, Calugaru E, et al. A comprehensive review of CT-based dosimetry parameters and biochemical control in patients treated with permanent prostate brachytherapy. *Int J Radiat Oncol Biol Phys* 2001;50:605–14.
- [63] Potters L, Klein EA, Kattan MW, et al. Monotherapy for stage T1-T2 prostate cancer: radical prostatectomy, external beam radiotherapy, or permanent seed implantation. *Radiother Oncol* 2004;71:29–33.
- [64] Prestidge BR, Bice WS, Kiefer EJ, et al. Timing of computed tomography-based postimplant assessment following permanent transperineal prostate brachytherapy. *Int J Radiat Oncol Biol Phys* 1998;40:1111–5.
- [65] Ragde H, Elgamel AA, Snow PB, et al. Ten-year disease free survival after transperineal sonography-guided iodine-125 brachytherapy with or without 45-gray external beam irradiation in the treatment of patients with clinically localized, low to high Gleason grade prostate carcinoma. *Cancer* 1998;83:989–1001.
- [66] Ragde H, Korb LJ, Elgamel AA, et al. Modern prostate brachytherapy. Prostate specific antigen results in 219 patients with up to 12 years of observed follow-up. *Cancer* 2000;89:135–41.
- [67] Rivard MJ et al. Update of AAPM TG 43: a revised AAPM protocol for brachytherapy dose calculations. *Med Phys* 2004;31:633–74.
- [68] Roberson PL, Narayana V, McShan DL, et al. Source placement error for permanent implant of the prostate. *Med Phys* 1997;24:251–7.
- [69] RTOG 98-05. Phase II Trial of transrectal ultrasound guided permanent radioactive implantation of the prostate for definitive management of localized adenocarcinoma of the prostate.
- [70] Sharkey J, Cantor A, Solc Z, et al. 103Pd brachytherapy versus radical prostatectomy in patients with clinically localized prostate cancer: a 12-year experience from a single group practice. *Brachytherapy* 2005;4:33–4.
- [71] Siebert FA, Kohr P, Kovacs G. The design and testing of a solid phantom for the verification of a commercial 3D seed reconstruction algorithm. *Radiother Oncol* 2005;74:169–75.

- [72] Sommerkamp H, Rupprecht M, Wannemacher M. Seed loss in interstitial radiotherapy of prostatic carcinoma with ^{125}I . *Int J Radiat Oncol Biol Phys* 1988;14:389–92.
- [73] Stamey TA, McNeal JE, Freiha FS, et al. Morphometric and clinical studies on 68 consecutive radical prostatectomies. *J Urol* 1988;139:1235–41.
- [74] Stock RG, Stone NN. Importance of post-implant dosimetry in permanent prostate brachytherapy. *Eur Urol* 2002;41:434–9.
- [75] Stock RG, Stone NN, Lo YC, et al. Postimplant dosimetry for ^{125}I prostate implants: definitions and factors affecting outcome. *Int J Radiat Oncol Biol Phys* 2000;48:899–906.
- [76] Stone NN, Stock RG. Prostate brachytherapy, treatment strategies. *J Urol* 1999;162:421–6.
- [77] Su Y, Davis BJ, Herman MG, et al. Examination of dosimetry accuracy as a function of seed detection rate in permanent prostate brachytherapy. *Med Phys* 2005;32:3049–56.
- [78] Todor DA, Zaider M, Cohen GN, et al. Intraoperative dynamic dosimetry for prostate implants. *Phys Med Biol* 2003;48:1153–71.
- [79] Trinchieri A, Moretti R. Trends in prostate cancer epidemiology in the year 2000. *Arch Ital Urol Androl* 2005;77:164–6.
- [80] Tsodikov A, Szabo A, Wegelin J. A population model of prostate cancer incidence. *Stat Med* 2006.
- [81] Van Gellekom MP, Moerland MA, Kal HB, et al. Biologically effective dose for permanent prostate brachytherapy taking into account postimplant edema. *Int J Radiat Oncol Biol Phys* 2002;53:422–33.
- [82] Wallner K, Roy J, Harrison L. Dosimetry guidelines to minimize urethral and rectal morbidity following transperineal ^{125}I prostate brachytherapy. *Int J Radiat Oncol Biol Phys* 1995;32:465–71.
- [83] Waterman FM, Yue N, Corn BW, et al. Effect of prostatic edema on CT-based postimplant dosimetry. *Int J Radiat Oncol Biol Phys* 1998;41:1069–77.
- [84] Williamson JF, Coursey BM, DeWerd LA, et al. Recommendations of the American Association of Physicists in Medicine on ^{103}Pd interstitial source calibration and dosimetry: implications for dose specification and prescription. *Med Phys* 2000;27:634–42.
- [85] Yan Y et al. Permanent prostate seed implant brachytherapy: report of the AAPM TG 64. *Med Phys* 1999;26:2054–76.
- [86] Yue N, Chen Z, Peschel R, et al. Optimum timing for image-based dose evaluation of ^{125}I and ^{103}Pd prostate seed implants. *Int J Radiat Oncol Biol Phys* 1999;45:1063–72.
- [87] Zelefsky MJ, Yamada Y, Marion C, et al. Improved conformity and decreased toxicity with intraoperative computer-optimized transperineal ultrasound-guided prostate brachytherapy. *Int J Radiat Oncol Biol Phys* 2003;55:956–63.